

Polarized Polychromatic Noncoherent Light (Biopton Light) as Adjunctive Treatment in Chronic Oral Mucosal Pain: A Pilot Study

Massimo Petruzzi, DDS, PhD,¹ Gianna Maria Nardi, BSDH,² Fabio Cocco, DCS, PhD,³
Fedora della Vella, DDS,¹ Roberta Grassi, DDS,³ and Felice Roberto Grassi, MD, DMD, PhD¹

Abstract

Objective: Aim of this study was to assess the efficacy of polarized polychromatic noncoherent light (Biopton light) in the treatment of chronic oral mucosal pain (COMP).

Patients and methods: Twenty-two patients affected by COMP were treated with standardized pharmacological protocols in association with Biopton light (90 W; light wavelength=480–3400 nm; degree of polarization=95%; specific power density=40 mW/cm²; energy density=2.4 J/cm). The outcome measures were intensity of pain [measured by visual analog scale (VAS) score] and signs reduction (measured by Eisen score) recorded at baseline (t_0), after 4 weeks (t_1), and after 8 weeks (t_2). Signs and symptoms scores were compared with those of a cohort of comparable patients selected from institutional medical record files.

Results: Patients in pharmacological treatment associated with Biopton showed a significant VAS score decrease at t_1 and t_2 ($t_0=6.9$, $t_1=3.9$, $t_2=1.8$, $p<0.05$), whereas the patients in exclusive pharmacological treatment showed a significant VAS score improvement only at t_2 . Comparing the VAS score at t_1 and t_2 in the two groups, a significant improvement was recorded in patients undergoing Biopton adjunctive treatment ($t_1=3.9$ vs. 5.9; $p<0.05$ and $t_2=1.8$ vs. 3.6; $p<0.05$). In both groups Eisen score improved at t_1 and t_2 , but in the Biopton-treated patients the improvement was statistically better at t_1 (1.9 vs. 0.8; $p<0.05$) and at t_2 (2.7 vs. 1.4; $p<0.05$).

Conclusions: In COMP patients, Biopton use associated with pharmacological treatment allows a better and faster signs and symptoms reduction when compared with the exclusive pharmacological treatment. Further controlled studies are needed to establish the relative and absolute effectiveness of Biopton in COMP management.

Keywords: Biopton, oral mucosal pain, photobiomodulation

Introduction

CHRONIC ORAL MUCOSAL PAIN (COMP) is defined as a pain lasting >3 months and outlasting the inflammatory stimulus.¹ Different pathologies with different etiology and pathogenesis, induced by local or systemic factors, can cause COMP. Although Zakrzewska reports that chronic orofacial pain in its broadest definition can affect up to 7% of the population, there are no epidemiological data about the exact incidence and prevalence of COMP, considered a subset of patients suffering from chronic orofacial pain.² The main causes of this lack of epidemiological data are probably due

to the extreme variety of clinical conditions that can generate chronic pain affecting the oral mucosa and the lack of a consensus and guidelines that define the criteria to diagnose the COMP. The most common causes of COMP are burning mouth syndrome (BMS), oral erosive lichen planus, recurrent aphthous stomatitis, vesiculobullous diseases and chronic ulcerations.³ The chronic pain is often characterized by a burning, stinging, or sore sensation that impairs the patients' quality of life and increases the risk of psychological morbidities such as anxiety and depression.^{2–4}

Pharmacological treatment includes systemic and/or topical corticosteroids, bioadhesive and mucoprotective agents,

¹Interdisciplinary Department of Medicine—Section of Dentistry, Dental School, University “Aldo Moro” of Bari, Bari, Italy.

²Department of Oral and Maxillo Facial Sciences, Dental School, University “La Sapienza” of Rome, Rome, Italy.

³Department of Surgical, Microsurgical and Medical Sciences, Dental School, University of Sassari, Sassari, Italy.

polyvitaminic complexes, benzodiazepines, and anesthetic ointments.^{5,6} However, the chronic use of drugs in COMP patients can cause side and/or undesired effects or be ineffective; also for these reasons, new therapeutic strategies have been employed to limit pain and the consequent patients' frustration.^{7,8}

In recent years, the use of phototherapy is increasing and also applied to the management of COMP. In fact, a large number of authors report about the effectiveness of the photobiomodulation induced by low-level laser therapy (LLLT), photodynamic therapy, and polarized polychromatic noncoherent light in COMP patients.^{9–11}

The rationale is the interaction between photons and a wide range of molecules thanks to scattering and absorption processes. The photonic energy interacts with the molecules inducing photochemical and photobiological effects, such as the generation of reactive radicals (reactive oxygen species) and singlet oxygen, destruction of enzymes in cellular signaling pathways, the opening of ion channels, and the promotion of specific gene expression.^{12–14}

The aim of this study was to evaluate the effectiveness of photobiomodulation with polarized light in the coadjuvant treatment of COMP.

Patients and Methods

Sample size definition

Power analysis, using one-sided confidence interval, was performed to identify a proper sample size.

The standardized effect was set at 0.40, with a sample size of 18 subjects and an upper 80% one-sided confidence limit of 0.3967.¹⁵

Patients' data

Twenty-two patients aged 18 years or older, suffering from COMP were enrolled. In COMP patients were included those affected by atrophic-erosive lichen planus, mucous membrane pemphigoid, pemphigus vulgaris, chronic oral ulcerations, BMS, and oral systemic lupus erythematosus (SLE). The diagnosis was confirmed by histopathological examination and direct immunofluorescence in case of oral lichen, pemphigus, pemphigoid, and oral SLE. Patients with histopathological evidence of dysplasia (mild, moderate, and severe), in chemo-radio treatment or assuming analgesic, anti-inflammatory or psychoactive drugs, or with a previous medical history of melanoma, actinic cheilitis, actinic pigmentosus, and xeroderma pigmentosum were excluded.

The study was conducted according to the Declaration of Helsinki and approved by the Institution's Ethical Committee. A written informed consent was obtained from every patient before participation in the study.

Enrolled patients' data were compared with those of a cohort of patients comparable for gender, age, comorbidities, diagnosis of oral disease, and treatment regimen, selected from the medical record files of the Dental Clinic of University "Aldo Moro" of Bari.

Oral mucosal signs and symptoms assessment

Two blinded independent clinicians calibrated in pair evaluated the signs evolution of the oral lesions. Presence of

erosions, ulcerations, and atrophy was recorded and photographed for each patient. Signs improvement was scored according to Eisen¹⁶: 0=no change or worsening; 1=light improvement (20–50%); 2=marked improvement (50–80%); and 3=healing (80–100%). The 10 points score of visual analog scale (VAS) was used for pain recording.

Symptoms were recorded at the beginning before starting the treatment (t_0), at the end of the fourth week (t_1), and at the end of the eighth week (t_2), whereas Eisen score was evaluated at t_1 and t_2 .

Photobiomodulation treatment intervention

A Biopton-2 phototherapeutic device (Biopton AG, Wollerau, Switzerland) was used for the irradiation of the oral mucosa with the following output characteristics: rated power of halogen=90 W; light wavelength=480–3400 nm; degree of polarization=95%; specific power density=40 mW/cm²; and energy density=2.4 J/cm. The duration of each treatment session was 15 min. Biopton light was positioned 10 cm from the oral mucosa and a C-shaped mouth opener was positioned for the entire duration of the session (Fig. 1). Two weekly sessions for 8 weeks were planned.

Pharmacological treatment

Patients affected by atrophic-erosive lichen planus, mucous membrane pemphigoid, and oral SLE were treated with clobetasol propionate cream 0.05% in Orabase, twice a day for 8 weeks. Oral pemphigus vulgaris patients were treated with prednisone *per os* [0.5 mg/(kg·die)]. Prednisone was tapered according to lesions remission. Chronic oral

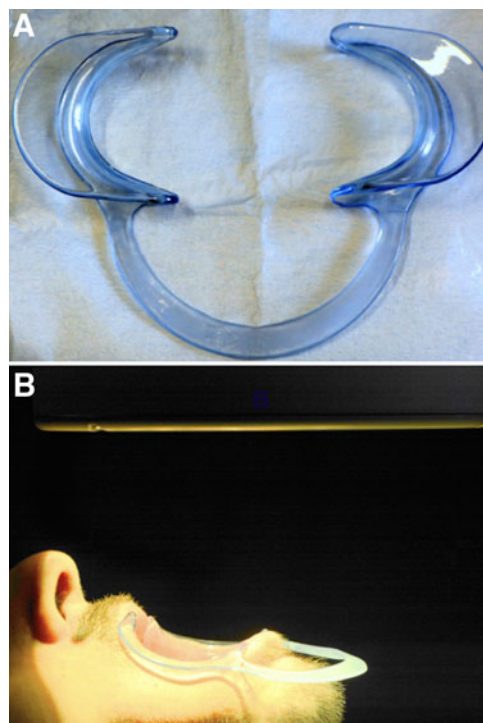


FIG. 1. (A) C-shaped device. (B) Patient wearing the C-shaped device during Biopton treatment.

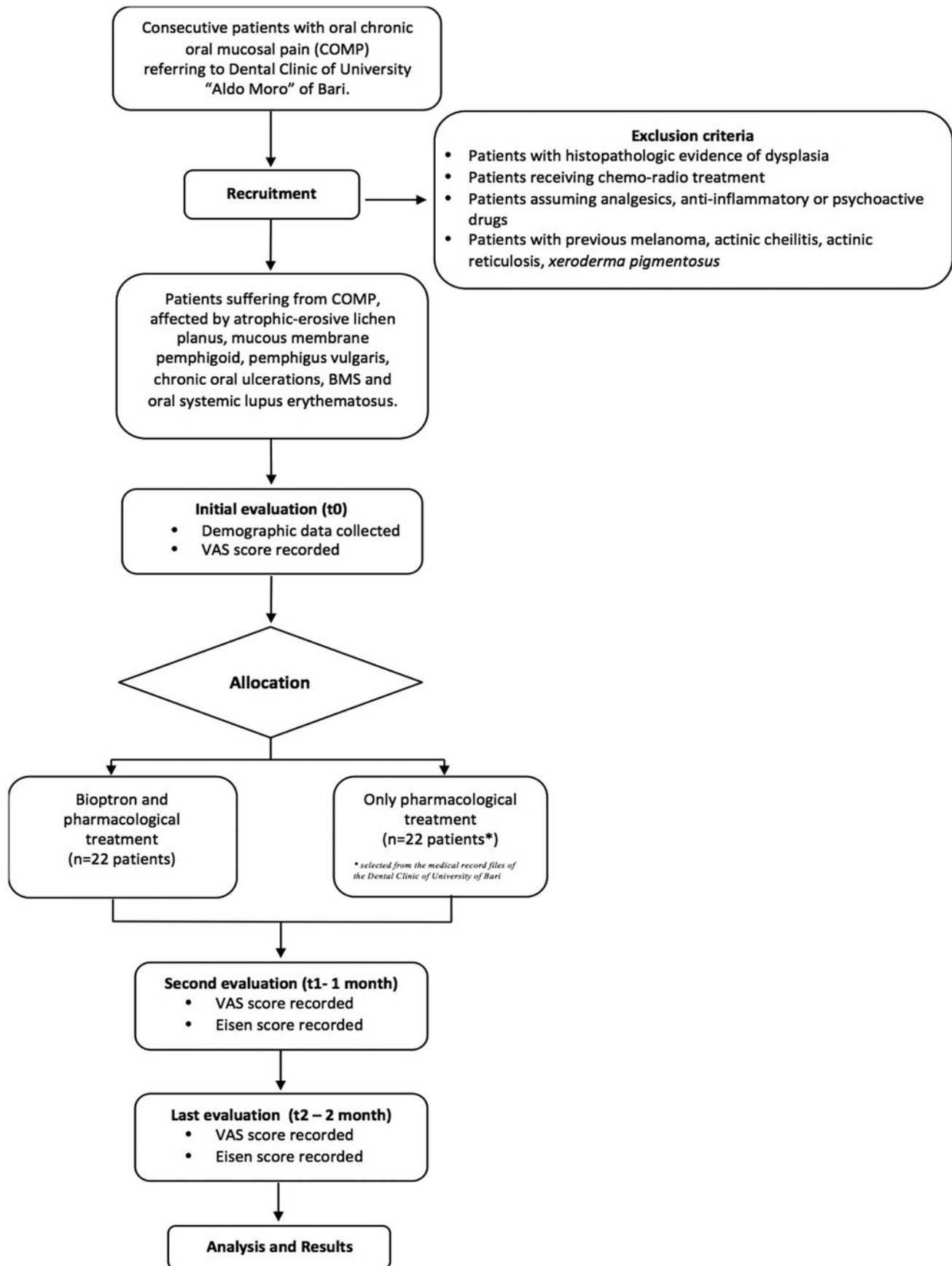


FIG. 2. Flowchart resuming patients' enrollment criteria.

TABLE 1. DEMOGRAPHIC CHARACTERISTICS AND CAUSE OF CHRONIC ORAL MUCOSAL PAIN IN THE TWO GROUPS

Cause of COMP	No. of patients		Age (years)		Male/female	
	Enrolled	Control ^a	Enrolled	Control ^a	Enrolled	Control ^a
Oral lichen planus	6	6	66.0±4.9	65.5±7.7	4/2	4/2
Mucous membrane pemphigoid	2	2	56.0±2.0	58.3±1.5	0/2	0/2
Pemphigus vulgaris	1	1	61.0	60.0	1/0	1/0
Chronic oral ulcerations	4	4	43.7±8.3	42.0±11.2	2/2	2/2
Oral SLE	1	1	56.0	53.0	0/1	0/1
Burning mouth syndrome	8	8	60.4±8.8	59.4±7.9	1/7	1/7
Total	22	22	58.2±10.3	57.7±11.2	8/14	8/14

^aSelected from the medical record files of the Dental Clinic of University of Bari. COMP, chronic oral mucosal pain; SLE, systemic lupus erythematosus.

ulcerations were treated with a chlorhexidine 0.12% gel alternated to a hyaluronic acid gel. Alpha-lipoic acid capsules 400 mg twice a day were prescribed to patients affected by BMS.

Data analysis and statistics

Statistical analyses were performed using a STATA 13 (www.stata.com).

VAS and Eisen score variations in each group before and after each treatment were compared using one-way analysis of variance (ANOVA), whereas intergroup differences were analyzed using repeated 0.05.ce ANOVA. Differences between means were considered significant for $p \leq 0.05$. The study protocol is resumed in Fig. 2.

Results

Twenty-two patients affected by COMP were enrolled in this study. The oral mucosal pain was caused by oral lichen planus (six patients), mucous membrane pemphigoid (two patients), pemphigus vulgaris (one patient), chronic oral ulcerations (four patients), oral SLE (one patient), and BMS (eight patients). The patients' characteristics at study entry (t_0) are reported in Table 1. Neither demographic nor VAS score differences were found between the two groups at baseline.

Patients who received photobiomodulation in addition to pharmacological treatment showed a significant VAS score decrease already after 4 weeks ($t_0=6.9$ to $t_1=3.9$; $p < 0.05$); VAS had a further significant reduction after 8 weeks ($t_1=3.9$ to $t_2=1.8$; $p < 0.05$). Patients who received only pharmacological treatment showed no significant VAS score improvement after 4 weeks ($t_0=6.5$ to $t_1=5.9$; $p=0.10$), whereas a significant improvement was observed only after

8 weeks of pharmacological treatment ($t_1=5.9$ to $t_2=3.6$; $p < 0.05$).

Comparing the two groups' VAS score at t_0 and t_1 , a significant improvement was recorded in patients who underwent photobiomodulation adjunctive treatment ($t_1=3.9$ vs. 5.9; $p < 0.05$ and $t_2=1.8$ vs. 3.6; $p < 0.05$). The Eisen score in the photobiomodulation-treated group statistically improved ($t_1=1.9$ to $t_2=2.7$; $p < 0.05$) as well as in the control group ($t_1=0.8$ to $t_2=1.4$; $p < 0.05$). However, the group of patients receiving adjunctive treatment with Bioptron showed a statistically significant improvement of Eisen score at t_1 (1.9 vs. 0.8; $p < 0.05$) and at t_2 (2.7 vs. 1.4; $p < 0.05$) compared with the control group. Table 2 summarizes the aforementioned data.

No side effects or adverse reactions were recorded.

Discussion

In this study, pain severity based on VAS score as well as oral signs evaluated by Eisen score showed a significant improvement in 8 weeks after the beginning of the treatment in both the groups. However, patients receiving additional treatment with photobiomodulation showed a faster and more effective improvement of symptoms and oral signs, compared with patients undergoing exclusively pharmacological therapy.

We also described for the first time, the opportunity to use a C-shaped mouth opener to facilitate irradiation of intraoral mucosal sites by the Bioptron light.

At the best of our knowledge, no studies evaluated the effect of Bioptron light therapy on patients with COMP: only a previous study,¹¹ limited to a subgroup of patients suffering from generic oral ulcerations, reported a marked exudation and pain reduction after 1 and 3 months, other

TABLE 2. SIGNS AND SYMPTOMS IN THE TWO GROUPS OF CHRONIC ORAL MUCOSAL PAIN PATIENTS

	t_0	t_1	t_2	t_0-t_1	t_1-t_2
VAS (mean ± SD)					
Bioptron+pharmacological treatment	6.9±0.7	3.9±0.8	1.8±1.1	$p < 0.05$	$p < 0.05$
Only pharmacological treatment	6.5±0.9	5.9±1.0	3.6±1.2	$p > 0.05$	$p < 0.05$
	$p > 0.05$	$p < 0.05$	$p < 0.05$		
Eisen score (mean ± SD)					
Bioptron+pharmacological treatment		1.9±0.8	2.7±0.6		$p < 0.05$
Only pharmacological treatment		0.8±0.4	1.4±0.5		$p < 0.05$
		$p < 0.05$	$p < 0.05$		

VAS, visual analog scale.

than infection improvement. The positive effects of photobiomodulation on the oral mucosa frequently concern the use of the laser technology. de Carvalho et al.¹⁷ demonstrated the laser and light emitting diode photobiomodulation efficacy on an animal model in accelerating the healing of formocresol-induced oral ulcers in both clinical and histological aspects. Also, in BMS patients, the photobiomodulation induced by LLLT significantly reduces the symptoms and represents an alternative to the conventional treatment regimens.¹⁸ Only six cases of oral pemphigoid treated with laser phototherapy are reported in literature, and all the authors agree to consider laser phototherapy a valuable treatment.¹⁹ LLLT is also employed in OLP: a recent meta-analysis concluded that LLLT seems to be a reliable alternative to corticosteroids for OLP treatment, lacking the adverse pharmacological effects.¹⁰

However, the photobiomodulation induced by Bioptron differs in several aspects from that induced by LLLT. In particular, the light used by the Bioptron technology is polychromatic and noncoherent although it is polarized such as the laser light. These characteristics allow to treat a larger area with a wider wave-width spectrum. Further, Bioptron use requires a simpler and quicker learning curve.²⁰

Wound healing and tissue repair, pain relief, and reduction on inflammation are the main clinical outcomes observed in several studies when photobiomodulation was used.²¹ The biological mechanisms that support the clinical effects are related to the upregulation of basic fibroblast growth factor [hepatocyte growth factor (HGF) and stem cell factor (SCF)], enhancement of cellular metabolism and vascularization (vascular endothelial growth factor increased production), cellular migration and differentiation, and an increased synthesis of various proteins involved in oxidative stress reduction, nociceptive pain transmission, and infection control.^{22–24}

The study does have limitations. We treated patients affected by heterogeneous pathologies (in some instances single cases, as pemphigus vulgaris or oral SLE) characterized by different etiopathogenesis and kind of pain; consequently, different photobiomodulation-related actions were involved in the pain and signs reduction. In particular, inflammation reduction obtained in the autoimmune diseases was probably due to NF- κ B expression and modulation, reduction of the proinflammatory cytokines levels in activated inflammatory cells, and phenotypical changes of the activated monocytes or macrophages.²⁵

The symptoms improvement achieved in patients affected by BMS is mainly due to the effects on the pain neural pathways and transmission. Photobiomodulation, in fact, seems to induce reversible morphological changes in neuronal cells. Specifically, it causes a decrease of mitochondrial membrane potentials, with a significant reduction of adenosine triphosphate (ATP) level. This affects the release of glutamate and its excitatory activity, attenuating neuronal hypersensitivity. These morphological changes only occur in cells with disrupted microtubule β -tubulin, indicator of an altered neural conduction. In addition, photobiomodulation inhibits the bradykinin stimulatory effect on A δ and C nociceptors.^{26,27}

Light therapy can help chronic oral ulcers healing process by stimulating the epithelial cells proliferation and migration, as well as improving blood flow into the affected site.

These processes are mediated by the increase of some cytokines, especially IF-1 β , TNF α , and MVP, which acti-

vate endothelial, fibroblastic, and epithelial growth factors themselves.^{17,28}

However, rather than analyzing separately the photobiomodulation effects on every single oral pathological condition, it would be appropriate to suppose that all the different biological mechanisms activated by the irradiation with Bioptron light act synergically in the clinical improvement of the analyzed patients.

The tremendous potential of low-dose biophoton therapies suggests further uses in oral and facial pain conditions, such as temporomandibular disorders, chronic periodontitis, and trigeminal neuralgia.²⁹ Initial positive results on the efficacy of photobiomodulation are also reported in the treatment of osteonecrosis of the jaws induced by bisphosphonates.³⁰

The use of photobiomodulation as adjunctive support to the pharmacological protocols is a valid choice in the management of signs and symptoms in course of COMP. Further studies on larger cohorts of patients are needed to confirm the data obtained in this pilot study and to explore the future potential applications in oral sciences.

Author Disclosure Statement

No competing financial interests exist.

References

1. Wolf E. Chronic orofacial pain. Understanding patients from two perspectives: the clinical view and the patient's experience. *Swed Dent J* 2006;181 Suppl:9–69.
2. Zakrzewska JM. Multi-dimensionality of chronic pain of the oral cavity and face. *J Headache Pain* 2013;14:37.
3. Hegarty AM, Zakrzewska JM. Differential diagnosis for orofacial pain, including sinusitis, TMD, trigeminal neuralgia. *Dent Update* 2011;38:396.
4. Rajan B, Ahmed J, Shenoy N, Denny C, Ongole R, Binnal A. Assessment of quality of life in patients with chronic oral mucosal diseases: a questionnaire-based study. *Perm J* 2014;18:e123–e127.
5. Stoopler ET, Sollecito TP. Oral mucosal diseases: evaluation and management. *Med Clin North Am* 2014;98:1323–1352.
6. Sheikh S, Gupta D, Pallagatti S, Singla I, Gupta R, Goel V. Role of topical drugs in treatment of oral mucosal diseases. A literature review. *N Y State Dent J* 2013;79:58–64.
7. Peters S, Goldthorpe J, McElroy C, et al. Managing chronic orofacial pain: a qualitative study of patients', doctors', and dentists' experiences. *Br J Health Psychol* 2015;20:777–791.
8. Alrashdan MS, Alkhader M. Psychological factors in oral mucosal and orofacial pain conditions. *Eur J Dent* 2017;11:548–552.
9. Kathuria V, Dhillon JK, Kalra G. Low level laser therapy: a panacea for oral maladies. *Laser Ther* 2015;24:215–223.
10. Hoseinpour Jajarm H, Asadi R, Bardideh E, Shafaei H, Khazaei Y, Emadzadeh M. The effects of photodynamic and low-level laser therapy for treatment of oral lichen planus-A systematic review and meta-analysis. *Photodiagnosis Photodyn Ther* 2018;S23:254–260.
11. Aragona SE, Grassi FR, Nardi G, et al. Photobiomodulation with polarized light in the treatment of cutaneous and mucosal ulcerative lesions. *J Biol Regul Homeost Agents* 2017;31(2 Suppl. 2):213–218.

12. Yun SH, Kwok SJJ. Light in diagnosis, therapy and surgery. *Nat Biomed Eng* 2017;1:0008.
13. Huang YY, Chen AC, Carroll JD, Hamblin MR. Biphasic dose response in low level light therapy. *Dose Response* 2009;7:358–383.
14. Huang YY, Sharma SK, Carroll J, Hamblin MR. Biphasic dose response in low level light therapy—an update. *Dose Response* 2011;9:602–618.
15. Cocks K, Torgerson DJ. Sample size calculations for pilot randomized trials: a confidence interval approach. *J Clin Epidemiol* 2013;66:197–201.
16. Eisen D, Ellis CN, Duell EA, Griffiths CEM, Voorhees JJ. Effect of topical cyclosporine rinse on oral lichen planus. A double-blind analysis. *N Engl J Med* 1990;323:290–294.
17. de Carvalho FB, Andrade AS, Rasquin LC, et al. Effect of laser (λ 660 nm) and LED (λ 630 nm) photobiomodulation on formocresol-induced oral ulcers: a clinical and histological study on rodents. *Lasers Med Sci* 2015;30:389–396.
18. dos Santos Lde F, de Andrade SC, Nogueira GE, Leão JC, de Freitas PM. Phototherapy on the treatment of burning mouth syndrome: a prospective analysis of 20 cases. *Photochem Photobiol* 2015;91:1231–1236.
19. Cafaro A, Broccoletti R, Arduino PG. Low-level laser therapy for oral mucous membrane pemphigoid. *Lasers Med Sci* 2012;27:1247–1250.
20. Heiskanen V, Hamblin MR. Photobiomodulation: lasers vs. light emitting diodes? *Photochem Photobiol Sci* 2018;17:1003–1017.
21. Arany PR. Craniofacial wound healing with photobiomodulation therapy: new insights and current challenges. *J Dent Res* 2016;95:977–984.
22. Feehan J, Burrows SP, Cornelius L, et al. Therapeutic applications of polarized light: tissue healing and immunomodulatory effects. *Maturitas* 2018;116:11–17.
23. Hamblin MR. Mechanisms and mitochondrial redox signaling in photobiomodulation. *Photochem Photobiol* 2018;94:199–212.
24. Iordanou P, Lykoudis EG, Athanasiou A, et al. Effect of visible and infrared polarized light on the healing process of full-thickness skin wounds: an experimental study. *Photomed Laser Surg* 2009;27:261–267.
25. Hamblin MR. Mechanisms and applications of the anti-inflammatory effects of photobiomodulation. *AIMS Biophys* 2017;4:337–361.
26. Chow RT, Armati PJ. Photobiomodulation: implications for anesthesia and pain relief. *Photomed Laser Surg* 2016;34:599–609.
27. Janzadeh A, Nasirinezhad F, Masoumpoor M, Jameie SB, Hayat P. Photobiomodulation therapy reduces apoptotic factors and increases glutathione levels in a neuropathic pain model. *Lasers Med Sci* 2016;31:1863–1869.
28. Wagner VP, Curra M, Webber LP, et al. Photobiomodulation regulates cytokine release and new blood vessel formation during oral wound healing. *Lasers Med Sci* 2016;31:665–671.
29. Rahman SU, Mosca RC, Govindool Reddy S, et al. Learning from clinical phenotypes: low-dose biophotonics therapies in oral diseases. *Oral Dis* 2018;24:261–276.
30. da Guarda MG, Paraguassú GM, Cerqueira NS, Cury PR, Farias JG, Ramalho LM. Laser GaAlAs (λ 860 nm) photobiomodulation for the treatment of bisphosphonate-induced osteonecrosis of the jaw. *Photomed Laser Surg* 2012;30:293–297.

Address correspondence to:
Massimo Petruzzi, DDS, PhD
University of Bari “Aldo Moro”
Department of Interdisciplinary Medicine
Policlinico di Bari—Clinica Odontoiatrica
Piazza G. Cesare 11
Bari 70124
Italy

E-mail: massimo.petruzzi@uniba.it

Received: October 6, 2018.
 Accepted after revision: December 20, 2018.
 Published online: March 20, 2019.