

Treatment of non-atopic dermatitis with polarized UV-free polychromatic light: A case report

Alberto Leguina-Ruzzi,¹
Kishan Rajnikant Raichura,²
Sarah Karis Tonks,² Semira Kwabi,³
Claudia Leitner⁴

¹Department of Mitochondrial Physiology, Institute of Physiology, Czech Academy of Sciences, Prague, Czech Republic; ²The Lovely Clinic, London, UK; ³Skin Clinic, London, UK; ⁴Bioptron AG, Wollerau, Switzerland

Abstract

Non-atopic dermatitis is a common inflammatory condition, which is potentially debilitating and can compromise life quality. Polarized ultraviolet-free polychromatic light is used as therapeutic option for the treatment of wound healing and dermatological conditions. It has not yet been tested in the management of non-atopic dermatitis. In this case report, we present a 67-year-old female patient who had suffered with moderate non-atopic dermatitis for the past 20 years, and had undergone multiple treatments during that time without significant improvement or relief from her symptoms. She was treated for six weeks only with daily light therapy applications (10 minutes/area). Our results showed that light therapy offered a significant reduction in erythema of the affected zones with a concomitant reduction in pruritus and dehydration of the skin, without side effects or discomfort.

Introduction

Non-atopic dermatitis (NAD) or eczema is a common inflammatory condition; potentially debilitating that can compromise quality of life. It is usually seen in childhood, but can onset within or persist into adulthood.¹ Diagnosis of NAD is based on the findings of the history and physical examination; exposure to possible exacerbating factors, such as aeroallergens, irritating chemicals, foods and emotional stress, should be investigated.²

Unfortunately, no specific laboratory findings or histologic features define NAD. Although elevated IgE levels are found in up to 80 percent of affected patients, but IgE levels are also elevated in patients with

other non-atopic diseases.³ Pruritus is a universal finding in NAD. The pruritus can be severe, sometimes causing sleep disruption, irritability and generalized stress for affected patients and family members. Pruritus leads to scratching that can result in secondary skin changes such as lichenification (thick accentuation of skin lines), excoriation and abrasions with breakdown of the skin barrier. Consequently, NAD has been referred to as *the itch that rashes* rather than the *rash that itches*.⁴ Xerosis (dry skin) is another characteristic skin finding in patients with NAD. Because xerotic skin is unable to hold moisture, it is less pliable and more likely to crack and fissure. Resultant skin barrier breakdown increases susceptibility to irritation and infection. Reversing xerosis is one of the key elements and goals in the treatment of NAD.⁵ Based on the presenting characteristics, it is possible to categorize levels of severity. For example, a moderate condition is characterized by areas of dry skin, frequent itching, erythema and a moderate impact on everyday activities and psychosocial wellbeing.⁶ The treatment of NAD targets underlying skin abnormalities such as xerosis, pruritus, superinfection and inflammation. Patients should also be educated about the chronic nature of the disease and the need for continued adherence to proper skin care. The first line of treatment is based on topical emollients, calcineurin inhibitors, corticoids followed by systemic immunomodulation drugs and ultraviolet (UV) phototherapy as appropriate for the severity of the condition.⁷

Light therapy including low level laser as a coherent source of light and polarized UV-free polychromatic no coherent light therapy (e.g., Bioptron light therapy systems, Bioptron, Switzerland) have been proposed as nonaggressive, safe and cost effective therapeutic option for the treatment of several musculoskeletal disorders and skin conditions.⁸ The Bioptron light therapy system is a device with an optical unit emitting light that is similar to a part of the electromagnetic spectrum produced by the sun but with no UV radiation, reducing the potential side effects to no more than transient redness.⁹⁻¹² The light emitted by Bioptron light therapy system can be characterized as polarized (its waves oscillate on parallel planes), polychromatic (wavelength: 480-3400 nm), incoherent (out of phase light, unlike laser light) and low energy light.¹⁰ These different wavelengths (480-3400 nm) of Bioptron light therapy devices penetrate the skin at different depths triggering and enhancing a variety of cellular processes with beneficial physiological effects;^{13,14} including resolution of

Correspondence: Alberto Leguina-Ruzzi, Department of Mitochondrial Physiology, Institute of Physiology, Czech Academy of Sciences, Vídeňská 1083 14220 Prague 4, Czech Republic.
Tel. +420.241062760 – Fax: +420.241062488.
E-mail: albertoandres.leguinaruzzi@fgu.cas.cz

Acknowledgments: the authors are grateful to the patient for her cooperation in preparing this case report.

Key words: Non-atopic dermatitis; Eczema; Polarized light; Light therapy.

Contributions: all the authors claim authorship and have made substantial contributions to the conception, drafting, and final version of the paper. The study was designed by ALR and CL. The data were collected by ALR. The clinical protocol was supervised by KRR, SKT and SK. The manuscript was co-written by all authors.

Conflict of interest: CL is a medical director at Bioptron AG, Wollerau, Switzerland, and reports personal fees from Bioptron AG outside the submitted work. The other authors declare no potential conflict of interest.

Funding: none.

Received for publication: 18 April 2019.
Revision received: 20 August 2019.
Accepted for publication: 21 August 2019.

This work is licensed under a Creative Commons Attribution NonCommercial 4.0 License (CC BY-NC 4.0).

©Copyright: the Author(s), 2019
Licensee PAGEPress, Italy
Clinics and Practice 2019; 9:1161
doi:10.4081/cp.2019.1161

inflammation and activation of the immune system,¹⁵⁻¹⁸ mitochondria activation,¹⁹ reduction of pain intensity,²⁰⁻²² wound healing and tissue repair²³⁻²⁹ vasodilatation and increased local and systemic circulation.^{30,31}

Bioptron light has so-called bio-stimulative effects: when applied to the skin, it stimulates generation of collagen, elastin among others light-sensitive intracellular biomolecules.³² This initiates cellular chain reactions and also triggers secondary responses not only limited to the treated skin area but can affect the whole body.⁹⁻¹²

The efficacy of light therapy including low level laser and polarized light on NAD has not been adequately investigated. There are studies evaluating the effect of classic phototherapy showing important side effects derived from the amount of UVA-UVB content,³³ and there are a few unpublished observations on the effectiveness of

polarized light (Biopton) in atopic dermatitis in predominantly children. In 3 unpublished case report studies documented in Eastern Europe, where 198 patients were treated daily with the Biopton device for atopic dermatitis.³⁴ Particularly in children with NAD, erythema, itching, cracks and excoriations due to scratching were decreased or eliminated. The authors of these unpublished reports conclude a good therapeutic effect for NAD and attributed the analgesic, anti-inflammatory, anti-pruritus and trophostimulating effects to the Biopton irradiation device. Improved skin elasticity by the 5th treatment was also noted, and after 1 week of treatment with the Biopton device lead to a disappearance of symptoms of lichenification. Furthermore, the Federal Educational Agency/Russian People's Friendship University has edited an exactly elaborated and very detailed guideline for physicians indicating the correct use of the Biopton light therapy system in dermatological indications.³⁵ Moreover, the Ministry of Public Health and Social Development of the Russian Federation has prepared a Manual for Physicians^{36,37} using polychromatic incoherent polarized light for several der-

matological, cosmetically and aesthetic-surgical indications. Yet, the clinical efficacy of polarized light was never published in a peer-reviewed journal. A previous study using a similar device, showed beneficial effects on 70 patients,²⁴ however the results are not conclusive nor accessible for the medical community at large. Therefore, we sought to investigate the clinical efficacy of polarized polychromatic noncoherent Light (Biopton) therapy in NAD with particular focus on itchiness, dryness and size of lesion areas.

Case Report

A 67-year-old Caucasian female patient presented with an intermittent moderate presentation of NAD for the last 20 years and had visited multiple specialists and had undergone several treatments in the last decade, which all proved ineffective for managing her condition. Three months before the first private consultation, she presented with signs of NAD on the palmar surface of the hands and the popliteal fossa. Firstly, she self-treated the areas with con-

tact use of emollients based on Bepanthol (an over the counter ointment). After 2 weeks of no improvement she consulted with a specialist and commenced topical steroid therapy with Mometasone 0.1% ointment every day for 1 week. As there was no improvement and an increase in dryness, the therapeutic strategy was changed to Betamethasone 0.1% every day for 1 week. Additionally, levocetirizine dihydrochloride (levocetirizine) (5 mg/day) antihistamine was added. No oral corticoids were used as previous medical history showed that the patient responded negatively to Prednisone 10 mg, presenting with a hypertensive crisis. Additionally, a skin allergy test (prick test) was performed and negative for the standard panel of allergens. The itchiness, redness and dryness failed to resolve and the patient decided to suspend treatments.

Furthermore, the patient's medical history was positive for controlled hypertension (treated with losartan 50 mg/twice daily, nebivolol 5 mg/day, amlodipine 5 mg daily) and Hashimoto's hypothyroidism (treated with 100 mcg levothyroxine daily).

Demographic characteristics at the start of treatment are summarized in Table 1.

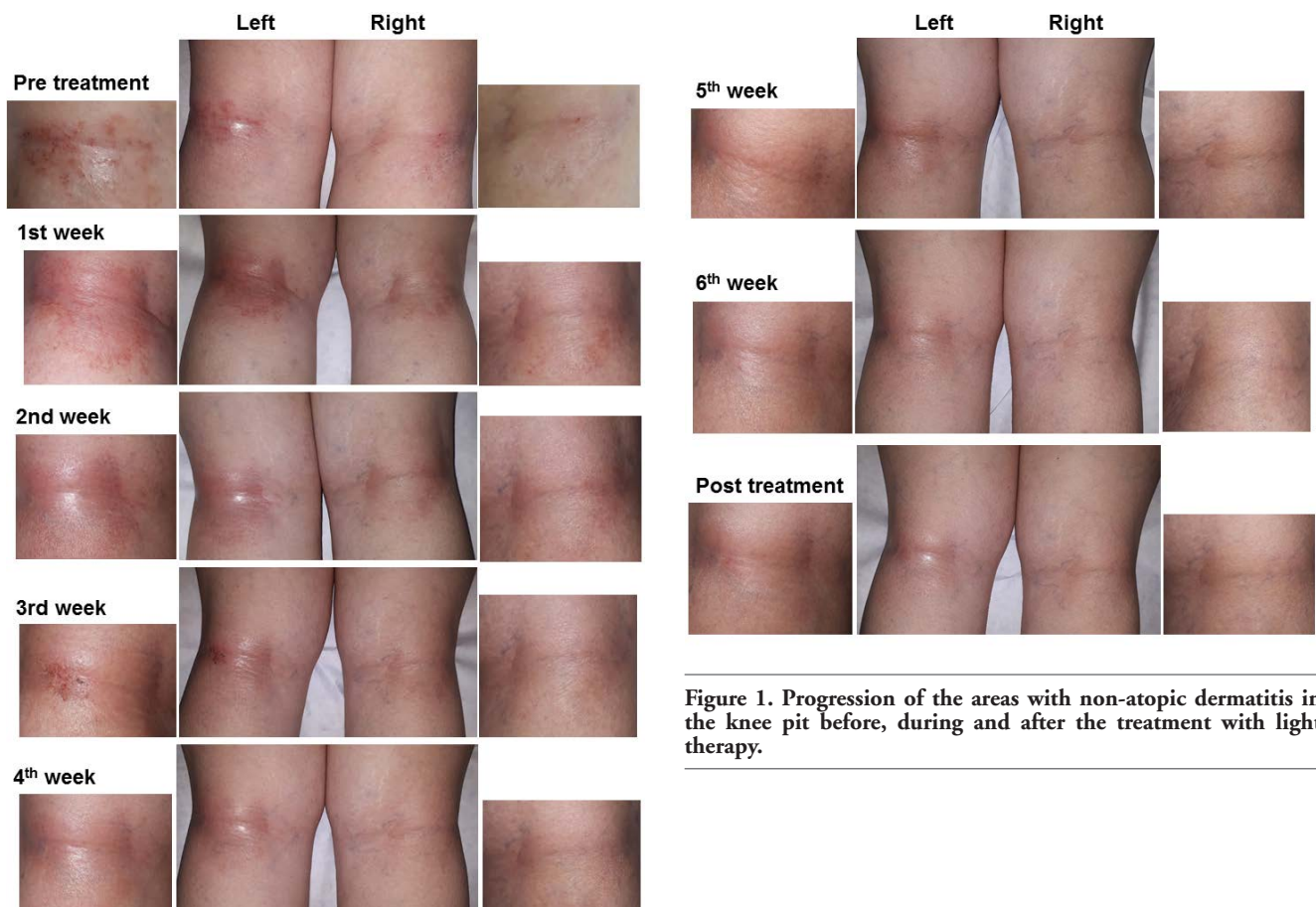


Figure 1. Progression of the areas with non-atopic dermatitis in the knee pit before, during and after the treatment with light therapy.

Polarized UV-free polychromatic light treatment

A Bioptron light therapy phototherapeutic device (Bioptron AG, Wollerau, Switzerland) with 5 cm treatment diameter (BIOPTRON MedAll®, 480-3400 nm, polarization level of 95%, power density 40 mW/cm², energy density 2,4 J/cm² per minute) was used for irradiation of the affected area of the skin. Polarized light therapy was administered daily for six weeks in a domiciliary care setting. Bioptron was placed at 90° to the surface and at a 10-cm distance from the cleaned skin area, for 10 minutes per section. The total treatment per day consisted of irradiation of five areas (total irradiation of 50 minutes). No emollient was used before and after the light exposure. One follow-up appointment was made 1 week after the completion of the 6-week treatment. The subject gave her informed consent for inclusion before she participated in the study. The study was conducted in accordance with the Declaration of Helsinki.

Outcome measures

Photo-documentation of the affected areas were assessed prior to treatment and on a weekly basis thereafter for a total of 7 weeks (6 weeks of treatment and 1 week of follow up after the therapy was completed). In addition, erythema, pruritus and dryness of skin were quantified on a weekly basis. Erythema (redness) and size of the skin area affected were quantified with by ImageJ (National Institutes of Health) according to standard procedures. Pruritus was assessed using a survey based 5-D itch scale.³⁸ Dryness of the skin was assessed according to a previously observational and self-assessment published scale.³⁹

Table 1. Clinical, demographic, biochemical and anthropometric characteristics.

Weight (Kg)	67
BMI (Kg/m ²)	29
Basal glucose (mg/dL)	79
Basal triglycerides (mg/dL)	110
Basal total cholesterol (mg/dL)	164
HDL	58
LDL	84
Systolic blood pressure (mmHg)	125
Diastolic blood pressure (mmHg)	68
Itch scale (0-25)	16.8
Dryness scale (1-4)	3 (severe)
Social habits	
Alcohol use	No
Smoking	No

BMI, body mass index; HDL, high-density lipoprotein; LDL, low-density lipoprotein.

Follow-up

In general, the patient reported a significant improvement in comfort with immediate resolution and relief from pruritic symptoms and erythema with the commencement of polarized light therapy. As shown in Figure 1, the patient initially presented with pruritus, active vesicles, redness and dryness in the popliteal fossa.

After the 1st week after commencing treatment an increase in redness was observed but it quickly improved from the 4th week to the end of the treatment. The quantification of the area and intensity confirmed the observations (Figure 2). Interestingly, at the 3rd week the patient presented an active lesion described by herself as a product of the use of tight trousers. This information suggests that the lesion was caused by friction and it resolved in seven days.

In the hands palms and wrist, the patient presented with small active breakable lesions (Figure 3) that showed a sustained reduction in redness and area with treatment of polarized light that starting from the 2nd week onwards (Figure 4).

Using the 5-D Itch Scale,⁴⁰ light therapy

reduces the itchiness starting from the 1st week, an effect that was sustained during and after the treatment (Figure 5A). Additionally, the polarized light improved the overall dryness of the skin (Figure 5B).

One week after completion of the 6-week therapy with polarized light, in the popliteal fossa there was a slight increase in redness and active vesicles, accompanied with a self-report of mild itchiness. In the hands, palms and wrist, however, no changes were observed after 1 week after therapy (without light therapy treatment). The overall dryness of the skin was slightly-negatively affected after one week without the treatment.

Discussion

The aim of this case study was to evaluate the effectiveness of polarized, UV-free, polychromatic light therapy in a patient with chronic NAD. This trial demonstrated an important improvement in our patient's symptoms (erythema, pruritus and area size) and presentation of chronic NAD with Bioptron light therapy treatment, and

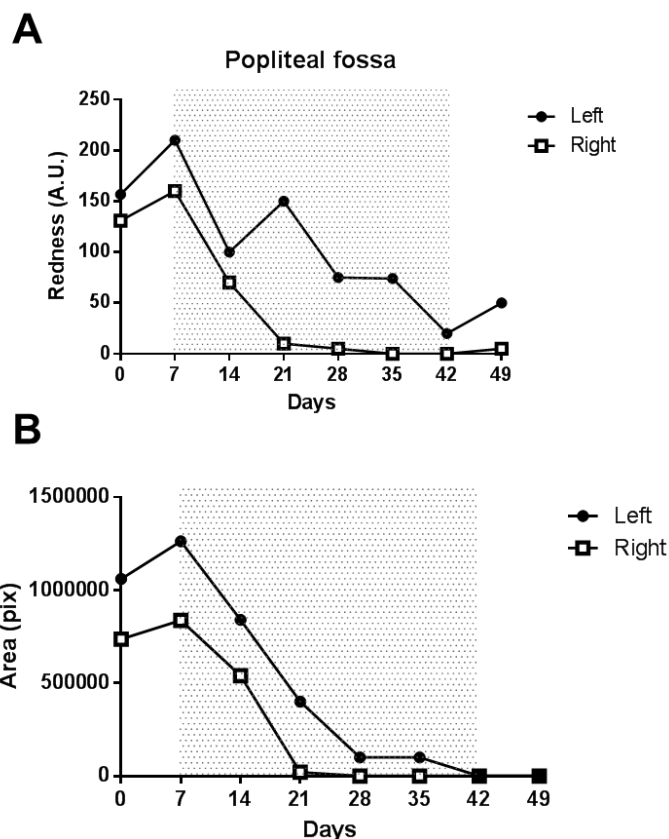


Figure 2. Semi quantification of (A) area and (B) redness intensity in knee pit non-atopic dermatitis sections before, during and after the treatment with light therapy.

reported welcomed comfort and relief from symptoms with less interference in her daily activities.

In this study, 6 weeks of Bioptron light therapy reduced erythema and lesion size in the hands and popliteal fossa. However, in the popliteal fossa, we observed an initial increase on redness and its size with treatment, but this was not associated with active vesicles or flakes, and moreover resolved after the 3rd week of light therapy treatment. In general, a significant reduction in itchiness and dryness was observed, increasing the patients comfort and overall adherence to the non-pharmacological treatment.

In this particular case the patient presented following a series of unsuccessful treatments in the last 20 years that caused

her frustration in regards to the condition. For that reason, it is pivotal to study new adjunctive therapies and implement measurements to increase the adherence to treatment regimens.^{40,41} Current treatments, particularly topic corticoids are associated with a poor adherence and compliance⁴² affecting long term effectiveness and control of the chronic condition.⁴³ Here, we report on a non-pharmaceutical and safe treatment method that was well tolerated by this patient.

Interestingly, the interruption of the treatment seems to reverse the benefits observed suggesting that polarized light would be required as an ongoing treatment alongside an established daily or weekly regimen. Polarized, UV-free, polychromatic light could be considered in cases of mild

NAD with limited and not extensive lesion areas when other interventions are not successful, associated with poor compliance or have failed to resolve symptoms for the patient.

Even when polarized, UV-free, polychromatic light has been tested for various conditions, such as cutaneous and mucosal ulcerative lesions,⁸ pressure ulcer healing,⁴⁴ acne vulgaris management,⁴⁵ diabetic foot complicated by atherosclerosis⁴⁶ and purulent-septic surgery,⁴⁷ more research is needed to understand its effect on NAD and other dermatological conditions. More clinical studies are needed to understand the therapeutic properties of polarized, UV-free, polychromatic light and to acknowledge its benefits, even though our findings suggest encouraging possibilities for the use

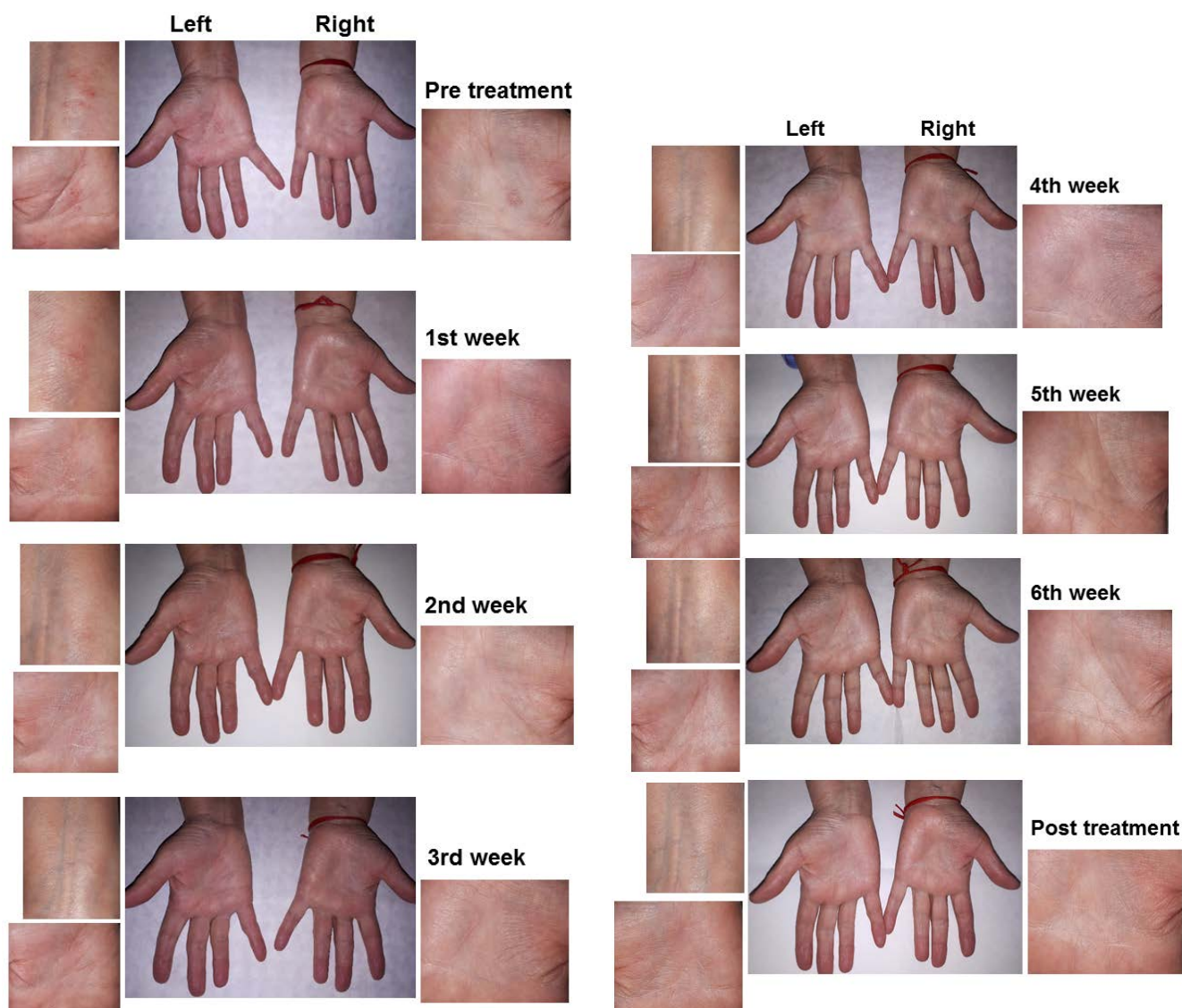


Figure 3. Progression of the areas with non-atopic dermatitis in the hands before, during and after the treatment with light therapy.

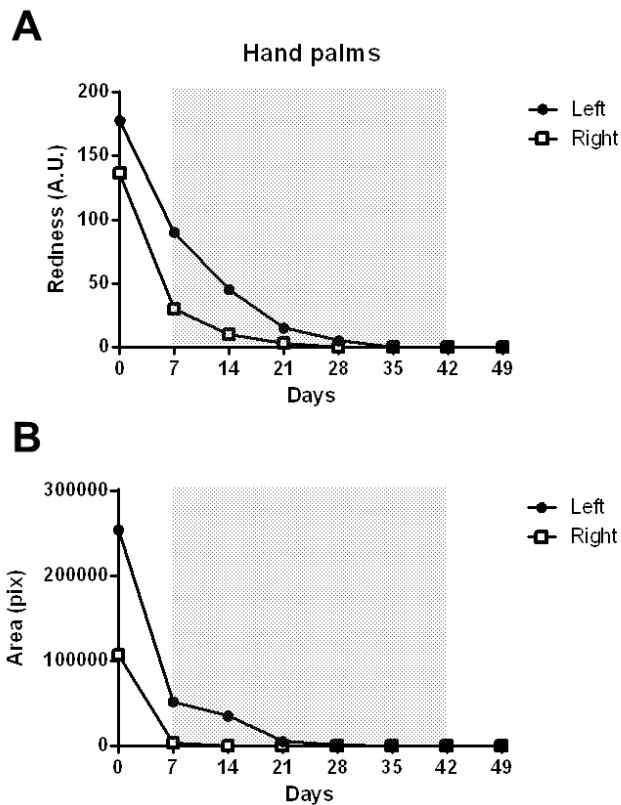


Figure 4. Semi quantification of (A) area and (B) redness intensity in hands non-atopic dermatitis sections before, during and after the treatment with light therapy.

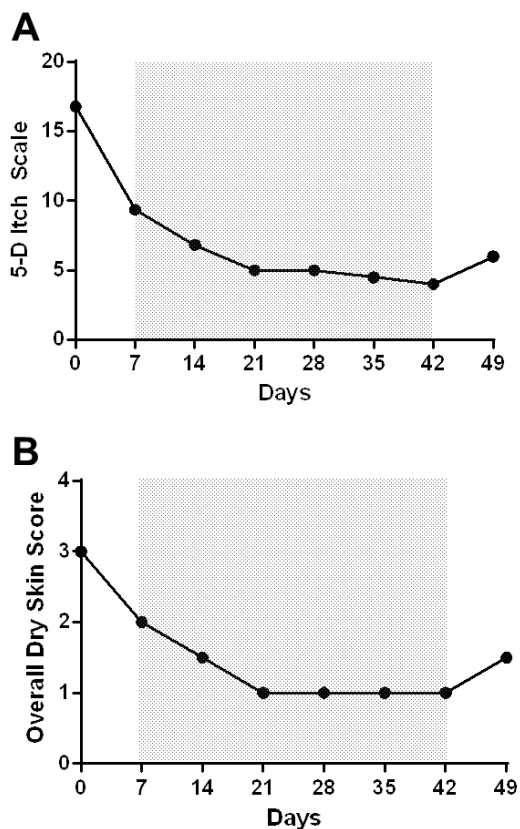


Figure 5. Overall quantification of (A) itchiness and (B) dryness based on weekly evaluations.

of this therapy as a management strategy for recurrent moderate NAD.

Conclusions

Our results suggest that polarized UV-free polychromatic light therapy may offer an effective treatment option for chronic NAD that is well tolerated and free of side effects.

References

1. Barrett M, Luu M. Differential diagnosis of atopic dermatitis. *Immunol Allergy Clin North Am* 2017;37:11-34.
2. Correale CE, Walker C, Murphy L, Craig TJ. Atopic dermatitis: a review of diagnosis and treatment. *Am Fam Physician* 1999;60:1191-8, 1209-10.
3. Leung DY. Atopic dermatitis: the skin as a window into the pathogenesis of chronic allergic diseases. *J Allergy Clin Immunol* 1995;96:302-18.
4. Clark RA, Kristal L. Atopic dermatitis. In: Sams WM, Lynch PJ, eds. *Principles and practice of dermatology*. 2nd ed. New York: Churchill Livingstone; 1996. pp 403-418.
5. Linde YW. Dry skin in atopic dermatitis. *Acta Derm Venereol Suppl (Stockh)* 1992;177:9-13.
6. Eichenfield LF, Ahluwalia J, Waldman A, et al. Current guidelines for the evaluation and management of atopic dermatitis: A comparison of the Joint Task Force Practice Parameter and American Academy of Dermatology guidelines. *J Allergy Clin Immunol* 2017;139:S49-57.
7. Hajar T, Gontijo JRV, Hanifin JM. New and developing therapies for atopic dermatitis. *An Bras Dermatol* 2018;93:104-7.
8. Aragona SE, Grassi FR, Nardi G, et al. Photobiomodulation with polarized light in the treatment of cutaneous and mucosal ulcerative lesions. *J Biol Regul Homeost Agents* 2017;31:213-8.
9. Nobuta S, Sato K, Nakagawa T, et al. Effects of wrist splinting for Carpal Tunnel syndrome and motor nerve conduction measurements. *Ups J Med Sci* 2008;113:181-92.
10. Reddy M, Gill SS, Kalkar SR, et al. Treatment of pressure ulcers: a systematic review. *JAMA* 2008;300:2647-62.
11. Begic-Rahic J, Vranic S. The application of Bioptron Light Therapy in dermatology and wound healing. *Eur Dermatol* 2010;5:57-60.

12. Kubasova T, Horváth M, Kocsis K, Fenyő M. Effect of visible light on some cellular and immune parameters. *Immunol Cell Biol* 1988;73:239-44.
13. Kubasova T, Fenyő M, Somosy Z, et al. Investigations on biological effect of polarized light. *Photochem Photobiol* 1988;48:505-9.
14. Zhevago NA, Samoilova KA, Obolenskaya KD. The regulatory effect of polychromatic (visible and infrared) light on human humoral immunity. *Photochem Photobiol Sci* 2004;3:102-8.
15. Zhevago N, Samoilova KA. Modulation of proliferation of peripheral blood lymphocytes after irradiation of volunteers with polychromatic visible and infrared light. *Cytology* 2004;46:567-77.
16. Zhevago NA, Zimin AA, Glazanova TV, et al. Polychromatic light (480-3400 nm) similar to the terrestrial solar spectrum without its UV component in post-surgical immune rehabilitation of breast cancer patients. *J Photochem Photobiol B* 2017;166:44-51.
17. Fenyő M, Mandl J, Falus A. Opposite effect of linearly polarized light on biosynthesis of interleukin-6 in a human B lymphoid cell line and peripheral human monocytes. *Cell Biol Int* 2002;26:265-9.
18. Fulga C. Antiinflammatory effect of laser therapy in rheumatoid arthritis. *Rom J Intern Med* 1998;36:273-9.
19. Karu TI, Pyatibrat LV, Afanasyeva NI. A novel mitochondrial signaling pathway activated by visible-to-near infrared radiation. *Photochem Photobiol* 2004;80:366-72.
20. Gulyar SA, Tamarova ZA. Physiological mechanisms of polarized light influence on pain. *Med Inform Engineer* 2016;1:41-6.
21. Gulyar SA, Tamarova ZA. Analgesic effects of the polarized red+infrared LED light. *J US-China Med Sci* 2017;14:47-57.
22. Limansky Y, Tamarova ZA, Gulyar SA. Suppression of pain by exposure of acupuncture points to polarized light. *Pain Res Manag* 2006;11:49-57.
23. Bogacheva ON, Samoilova KA, Zhevago NA, et al. Enhancement of fibroblast growth promoting activity of human blood after its irradiation in vivo (transcutaneously) and in vitro with visible and infrared polarized light. *Tsitologiya* 2004;46:159-71.
24. Białożył J, Materniak K, Kawecki M. Use of polarise lighting in support of treatment of pressure ulcers among patients after burns. Preliminary report. *Dermatol Estetyczna* 2018;20:R3-13.
25. Medeiros JL, Nicolau RA, Nicola EMD, et al. Healing of surgical wounds made with 970 nm diode laser associated or not with laser phototherapy (655nm) or polarized light (400-2000nm). *Photomed Laser Surg* 2010;28:489-97.
26. Medenica L, Lens M. The use of polarised polychromatic non-coherent light alone as a therapy for venous leg ulceration. *J Wound Care* 2003;12:37-40.
27. Iordanou P, Lykoudis EG, Athanasiou A, et al. Effect of visible and infrared polarized light on the healing process of full-thickness skin wounds: an experimental study. *Photomed Laser Surg* 2009;27:261-7.
28. Monstrey S, Hoeksema H, Saelens H, et al. A conservative approach for deep dermal burn wounds using polarised-light therapy. *Br J Plast Surg* 2002;55:420-6.
29. Monstrey S, Hoeksema H, Depuydt K, et al. The effect of polarized light on wound healing. *Eur J Plast Surg* 2002;24:377-82.
30. Samoilova KA, Bogacheva ON, Obolenskaya KD, et al. Enhancement of the blood growth promoting activity after exposure of volunteers to visible and infrared polarized light. I. Stimulation of human keratinocyte proliferation in vitro. *Photochem Photobiol Sci* 2004;3:96-101.
31. Samoilova KA, Obolenskaya KD, Vologdina AV, et al. Single skin exposure to visible polarized light induces rapid modification of entire circulating blood: I. Improvement of rheologic and immune parameters. *Proc SPIE* 1998;3569:90-103.
32. Bolton P, Dyson M, Young S. The effect of polarized light on the release of growth factors from the U-937 macrophage-like cell line. *Laser Ther* 1992;4:33-7.
33. Patrizi A, Raone B, Ravaioli GM. Management of atopic dermatitis: safety and efficacy of phototherapy. *Clin Cosmet Investig Dermatol* 2015;8:511-20.
34. Khan MA, Erdes SI. The application of BIOPTRON device polychromatic incoherent polarised light in cases of allergic diseases in children. *Pediatr Pract Moscow* 2010;70-2.
35. Kislyi ND. BIOPTRON light therapy in dermatocosmetology. Guideline of the Federal Educational Agency/Russian People's Friendship University. Moscow: Federal Educational Agency/Russian People's Friendship University; 2009.
36. Ivanov, OL, Khaldin AA, Kochergin NG, Monakhov SA. The application of polychromatic incoherent polarised light in dermatology, cosmetology and aesthetic medicine. Manual for Physicians. Moscow: Ministry of Public Health and Social Development of the Russian Federation; 2008.
37. Monakhov SA, Perminova MA, Shablīi RA, et al. [The methods of phototherapy for the treatment and prevention of chronic dermatose]. *Vopr Kurortol Fizioter Lech Fiz Kult* 2012;4:33-6.
38. Elman S, Hynan LS, Gabriel V, Mayo MJ. The 5-D itch scale: a new measure of pruritus. *Br J Dermatol* 2010;162:587-93.
39. Kang BC, Kim YE, Kim YJ, et al. Optimizing EEMCO guidance for the assessment of dry skin (xerosis) for pharmacies. *Skin Res Technol* 2014;20:87-91.
40. Patel NU, D'Ambra V, Feldman SR. Increasing adherence with topical agents for atopic dermatitis. *Am J Clin Dermatol* 2017;18:323-32.
41. Patel N, Feldman SR. Adherence in atopic dermatitis. *Adv Exp Med Biol* 2017;1027:139-59.
42. Misery L. Why is there poor adherence to topical corticosteroid therapy in atopic dermatitis? *Expert Rev Dermatol* 2012;7:5-7.
43. Snyder A, Farhangian M, Feldman SR. A review of patient adherence to topical therapies for treatment of atopic dermatitis. *Cutis* 2015;96:397-401.
44. Durović A, Marić D, Brdareski Z, et al. The effects of polarized light therapy in pressure ulcer healing. *Vojnosanit Pregl* 2008;65:906-12.
45. Hass HL. Therapeutic effects of the BIOPTRON light in cosmetic medicine. *Acne vulgaris. Krankenpfl J* 1998;36:394-5.
46. Tomashuk IP, Tomashuk II. [Clinical efficacy of alprostan in combination with "Biopton-II" rays and iruxolmiramistin in the treatment of the diabetic foot complicated by atherosclerosis]. *Klin Khir* 2001;8:49-51.
47. Desiateryk VI, Mikhno SP, Kryvyts'kyi IuM, Kostiuk SO. [Application of polarized light in purulent-septic surgery]. *Klin Khir* 2002;9:34-6.