

Complex Regional Pain Syndrome (Sudeck Atrophy) Prevention Possibility and Accelerated Recovery in Patients with Distal Radius at the Typical Site Fracture Using Polarized, Polychromatic Light Therapy

Mirjana I. Zlatkovic-Svenda, MD, PhD,^{1,2} Claudia Leitner, PhD,³
Biljana Lazovic, MD, PhD,⁴ and Dejana M. Petrovic, MD⁵

Abstract

Objective: Distal radius fracture (DRF) is one of the most frequent population fracture mostly affecting women, and frequently leading to complex regional pain syndrome (CRPS). Management of DRF and CRPS in gerontology is complex. The aim was to evaluate the use of polarized, polychromatic, low-energy light therapy combined with conventional treatment after DRF in gerontology and to follow up patients for CRPS emergence.

Materials and methods: After plaster removal, female patients ($n=52$) were divided into two groups. Group 1 ($n=26$) was treated with exercises and cryotherapy on the wrist and dorsal hand (control). Group 2 ($n=26$) was additionally treated with light therapy (Biopton).

Results: While pain decreased and supination and pronation improved in all patients after 15 days of therapy, pain reduction was accelerated and supination enhanced in the light therapy-treated group ($p<0.05$). None of the patients in the light therapy-treated group developed CRPS during the 6-month follow-up, compared with four patients (15.4%) in the control group ($p<0.05$). Complete hand fist-forming capacity was achieved in 19 patients (73.1%) in the light therapy-treated group compared with 16 patients (61.5%) in the control group ($p>0.05$).

Conclusions: Biopton light therapy combined with conventional therapy improves patient outcome after DRF in gerontology, compared with conventional treatment alone.

Keywords: complex regional pain syndrome, Sudeck, fractura radii loco typico, radial fracture, prevention, Biopton, laserotherapy, kriotherapy, light therapy, gerontology

Introduction

DISTAL RADIUS AT the typical site fracture (fractura radii loco typico)—distal radius fracture (DRF), largely known as a broken wrist (a fracture of the radius very close to the wrist)—is one of the most frequent population fractures, accounting for 10–18% of all fractures in adults.¹ Over the past 40 years, DRF has shown a constant progression in prevalence, which could partially be explained by an extension of the average life span in humanity.¹

Because of the unbalanced bone turnover that causes osteoporosis in climacteric and postmenopausal women,

even a minor trauma (accidental slip and fall at home or on the street) can cause DRF. Around 79% of cases are women, and incidences increase with age following the onset of menopause, with the peak in the 60- to 65-year period.² According to Omsland et al.³ women from the urban area have a 30% higher risk of developing DRF than those from rural areas, which might be connected with insufficient sun exposure and lack of vitamin D production, which is crucial for the maintenance of proper bone density.

Conventional DRF treatment comprises 3–4 weeks of immobilization followed by physiotherapy after removing the plaster. The aim of physiotherapy is to reach adequate range

¹Internal Medicine Specialist-Rheumatologist, Institute of Rheumatology, University of Belgrade School of Medicine, Belgrade, Serbia.

²University of East Sarajevo Medical Faculty, Republika Srpska, Lukavica, Bosnia and Herzegovina.

³Biopton AG, Wollerau, Switzerland.

⁴Internal Medicine Specialist, University Clinical Hospital Center Zemun, University of Belgrade School of Medicine, Belgrade, Serbia.

⁵Physical Medicine and Rehabilitation Specialist, The Belgrade City Institute of Gerontology, Belgrade, Serbia.

of wrist joint movement and to empower patients for their everyday lives. Diadynamic current or electromagnetic field therapy is mostly used for that purpose, added with cryotherapy and exercise. Cryotherapy and exercises are routinely used after DRF, in combination with diadynamic currents, but the latter one is mostly contraindicated in the elderly. Due to poor skin quality and skin atrophy in old people accompanied with sensitivity damage, as well as due to a number of comorbidities due to aging, the application of physical agents (diadynamic currents specifically) is limited in most cases. This highlights the need for adequate treatment options for the elderly.

Complex regional pain syndrome (CRPS) is one of the most common DRF complications, mostly occurring within the first 4 months after the fracture. Its prevalence is estimated at 39%⁴ and occurs in 4–7% of patients after the fracture surgery of the extremity.⁵

CRPS is one of the most ambiguous and obscured chronic pain conditions affecting the limb, named, according to internationally agreed taxonomy, as the CRPS since 1994.⁶ CRPS diagnosis is usually made based on symptoms and clinical findings. The main CRPS signs are the autonomic nervous system dysfunction and tropical changes of the skin. Initially changes in vasomotor activity and sensation are presented in the affected extremity, such as altered sensitivity to touch (i.e., allodynia and hyperalgesia to mechanical or thermal stimuli). Therefore, it is also known as *causalgia*, the shoulder-hand syndrome, algodystrophy, algoneurodystrophy, *Sudeck atrophy*, *reflex sympathetic dystrophy*, *reflex neurovascular dystrophy*, *post-traumatic dystrophy*, and fracture disease.⁷

There are three typical stages in the disease course of CRPS: stage I: sympathetic dysfunction with dermatomal distribution of the pain; stage II: progression to dystrophy shown as edema, hyperhidrosis, neurovascular instability, hair loss, ridging, dystrophic, brittle and discolored nails, skin rash, subcutaneous bleeding, neurodermatitis or ulcerative lesions, changes in temperature or coloring of the skin; stage III: transition from sympathetic pain to sympathetically independent pain presenting with different degrees of atrophy, frequently overshadowed by subcutaneous edema,⁵ and irreversible contractures and loss of limb function at the final stage, evident through reduced strength, decreased range of motion, tremor, and dystonia.

Stages I and II may be spread to other extremities in approximately one-third of the CRPS patients, and may also become generalized, which is an infrequent complication during the late stage,⁸ leading to altered body perception and proprioception.^{9,10}

All three CRPS stages are characterized by very intensive, sometimes unbearable pain, which significantly influences the patient's everyday life. CRPS is the most common complication after distal upper extremity fracture, caused by DRF, resulting in a delay in returning to work, diminished health-related quality of life, and increased likelihood of poor outcome and/or litigation.¹¹ CRPS is one of the most disabling conditions in aged women, presenting a real therapeutic challenge highlighting the need for its adequate prevention.

According to randomized controlled trials, physio- and occupational therapy are effective for CRPS treatment. The majority of patients are cured within the first year, whereas for a few individuals the disease progresses to a chronic

stage, characterized by “warm CRPS” to “cold CRPS” transition¹² involving autonomous dysfunction. In stage III, bisphosphonates, calcitonin, intravenous administration of ketamine, binders of free radicals, oral corticosteroids, and spinal cord stimulation are being used,⁵ although without major success.

Low-level laser therapy (LLLT) has also shown good improvement of the chronic pain symptoms¹³ once CRPS has been developed. Some studies suggest that light, whether in the form of LLLT radiation or from other cold light sources, benefits a variety of painful musculoskeletal and neurological conditions.^{14,15}

Light therapy (Biopton AG) has been shown to provide analgesic effects, improved microcirculation, and vasomotor function^{16–18} for a variety of illnesses and diseases due to its biostimulatory effects.^{19,20} The properties of this light therapy device includes polarized, polychromatic, incoherent, and low-energy light, which sets this device apart from other light therapy devices in the market. The different wavelengths (480–3400 nm) of Biopton light therapy devices penetrate the skin at different depths, triggering and enhancing a variety of cellular processes with beneficial physiological effects^{21,22} (including resolution of inflammation and activation of the immune system,^{23–26} mitochondria activation,²⁷ reduction of pain intensity,^{28–30} tissue repair,³¹ vasodilatation, and increased local and systemic circulation).^{18,32}

We selected Biopton light therapy, because it has a relatively large treatment area compared with LLLT and because it can be used by nonmedical staff at the patients' home. In contrast, LLLT should be used by medical staff on an already manifested syndrome, directly on hand pain points and strictly dosed.

Therefore, the aim of this study was to evaluate light therapy (polarized, polychromatic, noncoherent, low-energy radiation) application combined with cryotherapy and optimal exercises in patients after DRF and to investigate whether the risk of CRPS could be minimized.

Materials and Methods

Patients

From January 2014 to December 2017, the prospective study consequently included patients with DRF from the Belgrade City Institute of Gerontology to be treated with physiotherapy. A total of 55 female patients with DRF at the typical site were screened for the study. Treatment started immediately after removal of the plaster. Two patients were not included, because they had already developed CRPS under the plaster, and were treated accordingly. Follow-up of another patient could not be collected because the patient died from complications associated with heart failure, resulting in a full dataset of 52 female patients who were included in the study.

Two age-matched groups were randomly assigned at the beginning: group 1 (mean age 64.0 ± 6.9 years) consisted of female patients ($n=26$) with DRF who were treated with nonsteroid anti-inflammatory drugs, exercises, and cryotherapy on the wrist and dorsal side of the hand (control). Group 2 (mean age 62.0 ± 7.2 years) consisted of 26 female patients who were treated with the same protocol as group 1, but received Biopton (polarized, polychromatic, noncoherent, low-energy radiation) light in addition (intervention

group). All patients were treated at their own home and evaluated at days 0 (D0), 7 (D7), and 15 (D15) for pain [Visual Analogue Scale (VAS)], and at D7 and D15 for a range of wrist supination and pronation, and at D15 for hand fist-forming capacity and followed up for CRPS-induced complications for 6 months after completion of therapy.

Cryotherapy

Ice cubes (frozen at -20°C) of $\sim 2\text{ cm}^3$ were applied two times a day (12 h apart) for 5 min at the wrist and dorsal region of the hand with circular massage. The hand was dried afterward and wrapped in cotton fabric for 20 min after each ice massage.

Exercise

Kinesiotherapy exercises were performed to enhance the range of wrist motion, with particular focus on supination and pronation. Active exercise was carried out with physiotherapist assistance for 30 min daily. Assisted exercise began from the neutral position to a maximum of supination and pronation, limited by pain. Exercise for fist-forming capacity was performed with a small rubber ball, squeezed 20 times a day by the patient, limited by pain as well.

Biopton light therapy

A Biopton phototherapeutic device (Biopton AG, Wollerau, Switzerland) with 5 cm treatment diameter (Biopton MedAll; 480–3400 nm; polarization level 95%; power density 40 mW/cm^2 ; energy density $2.4\text{ J/cm}^2/\text{min}$) was used for irradiation of the dorsal hand region, according to manufacturer's recommendations (Table 1). Group 2 received Biopton light therapy for a total of 10 min per day on five points of the dorsal hand region (2 min each) at a distance of 10 cm for a period of 15 days (Fig. 1). Biopton light therapy, unlike laser light, contains polychromatic light in the visible and part of the infrared range (without ultraviolet radiation). Biopton light therapy has several benefits, but for the current purpose, improved microcirculation, vasomotor function, and analgesic effects are of clinical importance (Fig. 2).^{16–18}

Outcome measures

Pain was assessed at D0, D7, and D15; supination and pronation were measured at D7 and D15. Pain was assessed

TABLE 1. PARAMETERS OF LIGHT THERAPY DEVICE

Criteria	Specification
Wavelength	480–3400 nm
Degree of polarization	>95%, 590–1550 nm
Treatment diameter	5 cm
Rated power of halogen	20 W
Power density	40 mW/cm^2
Light intensity	10,000 lux
Light energy per minute	2.4 J/cm^2
Duration of each session	10 min
Light energy per session	24 J/cm^2
Number of daily sessions	15
Cumulative dose	360 J/cm^2

Model: Biopton MedAll, Biopton AG, Wollerau, Switzerland.



FIG. 1. Patient set-up before Biopton light therapy (simulated patient).

using the VAS, which is a unidimensional measure for pain intensity, performed on a 100-mm line. Patients were asked to draw a vertical mark on the line, expressing the level of their pain, on a scale from 0 to 100.

Range of wrist motion was assessed for pronation and supination movement capacity, expressed in degrees. Ninety degrees for supination and pronation are considered the full range of motion. Supination is defined as rotation from the neutral position of the hand and forearm so that the palm faces upwards. Pronation is defined as rotation of the hand and forearm from the neutral position so that the palm faces downwards. These measurements were not taken at baseline (D0) because of the inability of the wrist to perform such movements right after removing the plaster.

Patients were evaluated for the hand fist-forming capacity at the follow-up, because of the inability of the wrist to form a fist within the first weeks after injury.

All patients were followed up for 6 months for CRPS occurrence and hand fist-forming capacity. The main criteria for CRPS were chronic, intensive pain of the hand, limited range of movement, with or without diffuse swelling of the hand, and changes in skin temperature.

Ethics

The study was approved by the Gerontology Institute Ethical Committee. All subjects gave signed informed consent to participate. Patients were able to drop out from the study at any stage and without reason.

Statistical analysis

Results were analyzed by descriptive methods of statistics, as well as with nonparametric Mann-Whitney *U*-test for

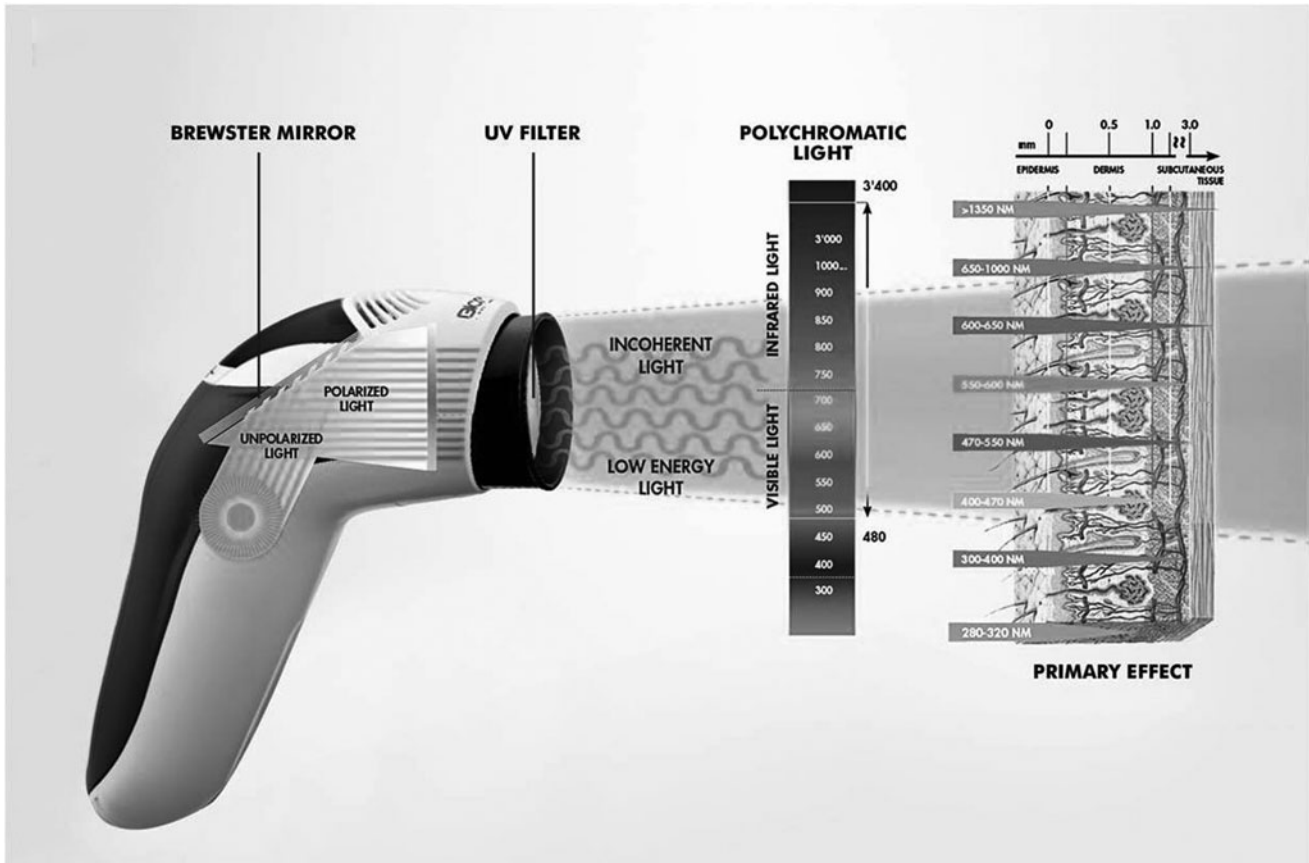


FIG. 2. Schematic representation of the light therapy device (Biopton MedAll, Biopton AG, Wollerau, Switzerland). The device used a Brewster mirror to create polarized light of low-energy levels. The polychromatic, incoherent wavelengths, excluding ultraviolet radiation, induce primary, biostimulatory effects on the skin.

independent samples and Wilcoxon signed rank test using SPSS 20.

Results

The average VAS values and range of motion, measured in the form of supination and pronation, are given in Table 2. Baseline (D0) VAS scores did not differ between

groups before treatment. All values (VAS scores, supination, and pronation) improved during the course of treatment, independent of the treatment group, but light therapy (group 2) accelerated pain relief ($p < 0.05$) and supination improvement ($p < 0.05$) at D15, compared with cryotherapy and exercise treatment alone (group 1). The range of motion for supination was already significantly improved at D7 and D15 for the light therapy-treated group compared with the

TABLE 2. VISUAL ANALOGUE SCALE VALUES, RANGE OF MOTION (SUPINATION AND PRONATION) IN GROUP 1 (CRYOTHERAPY AND EXERCISES) AND GROUP 2 (CRYOTHERAPY, EXERCISES, AND LIGHT THERAPY) AT BASELINE, 7, AND 15 DAYS OF THERAPY

	VAS			Supination			Pronation		
	Mean (SD)		p^a	Mean (SD)		p^a	Mean (SD)		p^a
	Group 1	Group 2	Gr1:Gr2	Group 1	Group 2	Gr1:Gr2	Group 1	Group 2	Gr1:Gr2
Day 0	37.7 (1.7)	33.1 (1.6)	0.251	—	—	—	—	—	—
Day 7	19.2 (1.2)	16.2 (0.9)	0.281	37.7 (5.7)	42.3 (7.4)	0.019*	49.7 (16.9)	52.1 (17.9)	0.167
Day 15	7.5 (9.8)	2.1 (2.6)	0.046*	47.3 (6.7)	56.1 (9.3)	0.001**	60.0 (13.1)	63.8 (14.0)	0.284
Day 7/day 15 ^b	0.000**	0.000**		0.000**	0.000**		0.000**	0.000**	

* $p < 0.05$, ** $p < 0.01$.

^aIndependent samples Mann-Whitney *U*-test.

^bRelated samples Wilcoxon signed rank test. VAS, Visual Analogue Scale.

control group (group 1; $p < 0.05$). Although pronation improved over time, no difference was found for pronation between treatment groups ($p > 0.05$).

At the 6-month follow-up period after completion of therapy, CRPS occurrence was significantly reduced in the light therapy-treated group compared with the control group ($p < 0.05$), 0% and 15.4%, respectively. Furthermore, at the follow-up, complete hand fist-forming capacity was achieved in 16 control group patients (group 1; 61.5%) and in 19 light therapy-treated group (group 2; 73.1%), although this did not reach statistical significance ($p = 0.375$).

Discussion

The aim of this study was to evaluate Bioptron light therapy (polarized, polychromatic, noncoherent, low-energy radiation) application combined with cryotherapy and optimal exercises in patients after DRF and to investigate the prevention of CRPS. We found that light therapy significantly accelerated pain relief and improved supination in elderly patients, compared with conventional treatment (cryotherapy and optimal exercises) alone. In addition, we found that the risk of CRPS could be minimized with light therapy, providing evidence that light therapy has significant benefits when used in combination with already existing therapy options for elderly patients with DRF.

The combination of light therapy, cryotherapy, and exercise showed good pain control and significant improvement of the wrist motion range. After therapy completion, none of the light therapy-treated patients developed the CRPS within the 6-month follow-up period, whereas 15.4% of patients treated with only cryotherapy and exercise did.

While this study has specifically selected the target group of elderly women with DRF, the higher age of participants and the specific minor trauma fracture are the current study limitations, so that the results cannot be directly extrapolated to all patients and patients with major or accidental trauma. Because of the limited number of subjects included in the study, it is also not clear whether light therapy not only reduces the incidence but also completely prevents CRPS development in elderly patients.

According to the literature, CRPS mostly occurs within the first 4 months after wrist fracture, with variations in incidence rates. Thomson McBride et al.³³ reported incidences of 20% within the first 10 weeks; Atkins et al.³⁴ reported 37.2% within the first 4 months, whereas Demir et al.³⁵ reported incidences as high as 58% for the first 3 months. This highlights the effective reduction in the risk and prevention option of light therapy with polarized, polychromatic, and low-energy properties.

More importantly, in the absence of efficient CRPS treatment for the elderly, finding patient-friendly therapy that aids its prevention is extremely vital.⁹ CRPS treatment is complex and limited, as there is no consistent information about efficiency of pharmaceutical agents, or effectiveness of other methods.³⁶ In fact, research synthesis of randomized controlled clinical trials found no significant analgesic effect for inhibiting sympathetic activity, including agents such as ganethidine, regional sympathetic blockers, calcitonin, codeine, magnesium chloride, propranolol, lorazepam, intravenous phentolamine, epidural clonidine, and intravenous regional blocks.³⁵

So far, only one prevention mechanism was explored by several randomized controlled trials, which included vitamin C usage after limb surgery with limited success.³⁷ Thus far, laser and other cold light sources have not been evaluated in DRF treatment and CRPS prevention therapy. Further studies on CRPS laser therapy and other cold light source treatment would be beneficial, especially in the light of possibilities for CRPS prevention. In line, exact protocols on dosage regimens should be evaluated.

Our results suggest that Bioptron light therapy strongly reduces the incidence rate of CRPS within the 6-month period after therapy, suggesting a long-lasting effect of low-energy light therapy. Polarized light penetrates deeper into the skin than other light sources, and the polychromatic wavelength properties ensure effective biostimulation of a variety of processes from different wavelengths.^{38–43}

Changes that occur and that may contribute to the therapeutic benefits observed in this study may include changes in membrane permeability of cells,^{44,45} stimulation of mitochondria for increased availability of adenosine triphosphate,²⁷ increased microcirculation through the stimulation of the synthesis of nitric oxide,^{18,32} stimulation of immune parameters and the human defense system (systemic effect),^{22–24} increased collagen synthesis from fibroblasts^{46–48} through the stimulation of macrophage-stimulating growth factors,⁴⁹ and alterations in pain perception.^{28–30} Due to polychromatic stimulation, and therefore the wide-ranging effects, the applications of this device are not only limited to wound healing and pain relief.

Evidence for the practical and clinical application of polarized, polychromatic light and its biostimulatory effects in sports medicine have also been investigated.^{50–54} Furthermore, polarized light therapy has also been associated with normalization of autonomic imbalance, and a shift in the balance from the sympathetic to parasympathetic autonomic homeostasis.⁵⁵ In patients with chronic glomerulonephritis, a single 10-min application of Bioptron light therapy led to improvements in the cardiac rhythm and a drop in the systolic and diastolic arterial pressure.⁵⁵

Recently, the use of polarized light in sympathetically mediated neuropathic pain,^{56,57} including CRPS,⁵⁸ revealed normalization of sympathetic functions, including decreased sympathetic hyperactivity and the integration of sympathovagal balance.⁵⁹ This form of treatment has been used as a noninvasive clinical application for managing a sympathetic blockade without any reported complications or side effects in the past for other indications.⁶⁰ Therefore, it is feasible that the observed analgesic effects and reductions in the occurrence of CRPS in our present study in patients after a distal radial fracture are associated also with a sympathetic blockade achieved by polarized polychromatic light therapy.

The low energy and incoherent properties of the light therapy device used in our study also ensures safe treatment of patients without side effects. Most importantly, this type of light therapy does not interfere with other treatment choices and is ideal for combining treatment regimes.

In summary, low-energy, polarized, and polychromatic light therapy combined with conventional therapy (cryotherapy and kinesiotherapy) in patients with DRF appears a better choice and treatment option for pain control improvement and a range of motion achievement; it also significantly reduces CRPS occurrence after DRF in gerontology.

Acknowledgments

The authors would like to thank the patients for their trust in the therapists, as well as the multidisciplinary team for the care of their patients.

Author Disclosure Statement

M.I.Z.-S., D.M.P., and B.L. declare they have no conflict of interests and that they were not funded for this work. Dr C.L., Medical Director of Bioptron, was consulted after data collection and supported the write-up only.

References

- Nellans KW, Kowalski E, Chung KC. The epidemiology of distal radius fractures. *Hand Clin* 2012;28:113–125.
- Hove LM, Fjeldsgaard K, Reitan R, et al. Fractures of the distal radius in a Norwegian city. *Scand J Plast Reconstr Surg Hand Surg* 1995;29:263–267.
- Omsland TK, Ahmed LA, Gronskog A, et al. More forearm fractures among urban than rural women: the NOREPOS study based on the Tromso study and the HUNT study. *J Bone Min Res* 2011;26:850–856.
- Li Z, Smith BP, Tuohy C, Smith TL, Andrew Koman L. Complex regional pain syndrome after hand surgery. *Hand Clin* 2010;26:281–289.
- Bruehl S. Complex regional pain syndrome. *BMJ* 2015;29:351.
- Merskey H, Bogduk N. Classifications of chronic pain: description of chronic pain syndromes and definition of pain terms. In: Report by the International Association for the Study of Pain Task Force on Taxonomy. H Merskey, N Bogduk (eds.). Seattle: IASP Press, 1994.
- Schott G. Complex. Regional? Pain? Syndrome? *Pain* 2007;7:145–157.
- Chelimsky T, Low PA, Naessens JM, Wilson PR, Amadio PC, O'Brien PC. Value of autonomic testing in reflex sympathetic dystrophy. *Mayo Clin Proc* 1995;70:1029–1040.
- Lewis JS, Kersten P, McPherson KM, et al. Wherever is my arm? Impaired upper limb position accuracy in complex regional pain syndrome. *Pain* 2010;149:463–469.
- Cohen H, McCabe C, Harris N, Hall J, Lewis J, Blake DR. Clinical evidence of parietal cortex dysfunction and correlation with extent of allodynia in CRPS type 1. *Eur J Pain* 2013;17:527–538.
- Förderreuther S, Sailer U, Straube A. Impaired self-perception of the hand in complex regional pain syndrome (CRPS). *Pain* 2004;110:756–761.
- Bruehl S, Maihöfner C, Stanton-Hicks M, et al. Complex regional pain syndrome: evidence for warm and cold subtypes in a large prospective clinical sample. *Pain* 2016;157:1674–1681.
- Turchin C. Laser therapy: new treatment for CRPS. *RSDSA Review*: 2010;23:4–5.
- Bjordal JM, Couppé C, Ljunggren AE. Low-level laser therapy for tendinopathy: evidence of a doseresponse pattern. *Phys Ther Rev* 2001;6:91–99.
- Kocic M, Lazovic M, Dimitrijevic I, Mancic D, Stankovic A. Evaluation of low level laser and interferential current in the therapy of complex regional pain syndrome by infrared thermographic camera. *Vojnosanit Pregl* 2010;67:755–760.
- Gulyar SA, Strelchenko II, Jelskii VN. Influence of polychromatic polarized light combined with near-infrared radiation on neurohumoral, immune and tissue changes at burn injury. *Med Inform Eng* 2016;2:15–20.
- Gulyar SA, Limansky Yu P, Tamarova ZA, Bidkov EG. Analgesic effects of BIOPTRON PILER Light. *Gen Pract J* 1999;4:21–23.
- Samoilova KA, Obolenskaya KD, Vologdina AV, Snopov SA, Shevchenko EV. Single skin exposure to visible polarized light induces rapid modification of entire circulating blood. 1. Improvement of rheologic and immune parameters. *Progress in Biomedical Optics/Proceedings of Low-Power Light on Biological Systems* 1998;3569:90–103.
- Fenyo M. Theoretical and experimental basis of biostimulation. *Optics Laser Technol* 1984;16:209–215.
- Sutherland JC. Biological effects of polychromatic light. *Photochem Photobiol* 2002;76:164–170.
- Kubasova T, Fenyo M, Somosy Z, Gazso L, Kertesz I. Investigations on biological effect of polarized light. *Photochem Photobiol* 1988;48:505–509.
- Zhevago NA, Samoilova KA, Obolenskaya KD. The regulatory effect of polychromatic (visible and infrared) light on human humoral immunity. *Photochem Photobiol Sci* 2004;3:102–108.
- Zhevago N, Samoilova KA. Modulation of proliferation of peripheral blood lymphocytes after irradiation of volunteers with polychromatic visible and infrared light. *Cytology* 2004;46:567–577.
- Zhevago NA, Zimin AA, Glazanova TV, et al. Polychromatic light (480–3400 nm) similar to the terrestrial solar spectrum without its UV component in post-surgical immune rehabilitation of breast cancer patients. *J Photochem Photobiol B* 2017;166:44–51.
- Fenyo M, Mandl J, Falus A. Opposite effect of linearly polarized light on biosynthesis of interleukin-6 in a human B lymphoid cell line and peripheral human monocytes. *Cell Biol Int* 2002;26:265–269.
- Fulga C. Antiinflammatory effect of laser therapy in rheumatoid arthritis. *Rom J Intern Med* 1998;36:273–279.
- Karu TI, Pyatibrat LV, Afanasyeva NI. A novel mitochondrial signaling pathway activated by visible-to-near infrared radiation. *Photochem Photobiol* 2004;80:366–372.
- Gulyar SA, Tamarova ZA. Physiological mechanisms of polarized light influence on pain. *Med Inform Eng* 2016;1:41–46.
- Gulyar SA, Tamarova ZA. Analgesic effects of the polarized Red+Infrared LED Light. *J US-China Med Sci* 2017;14:47–57.
- Limansky Y, Tamarova ZA, Gulyar SA. Suppression of pain by exposure of acupuncture points to polarized light. *Pain Res Manag* 2006;11:49–57.
- Bogacheva ON, Samoilova KA, Zhevago NA, et al. Enhancement of fibroblast growth promoting activity of human blood after its irradiation in vivo (transcutaneously) and in vitro with visible and infrared polarized light. *Tsi-tologija* 2004;46:159–171.
- Samoilova KA, Bogacheva ON, Obolenskaya KD, Blinova MI, Kalmykova NV, Kuzminikh EV. Enhancement of the blood growth promoting activity after exposure of volunteers to visible and infrared polarized light. I. Stimulation of human keratinocyte proliferation in vitro. *Photochem Photobiol Sci* 2004;3:96–101.
- Thomson McBride AR, Barnett AJ, Livingstone JA, Atkins RM. Complex regional pain syndrome (type 1): a comparison of 2 diagnostic criteria methods. *Clin J Pain* 2008;24:637–640.

34. Atkins RM, Duckworth T, Kanis JA. Features of algodystrophy after Colles' fracture. *J Bone Joint Surg Br* 1990; 72:105–110.
35. Demir SE, Ozaras N, Karamehmetoglu SS, Karacan I, Aytekin E. Risk factors for complex regional pain syndrome in patients with traumatic extremity injury. *Ulusal Travma Ve Acil Cerrahi Derg* 2010;16:144–148.
36. Perez RS, Kwakkel G, Zuurmond WW, de Lange JJ. Treatment of reflex sympathetic dystrophy (CRPS type 1): a research synthesis of 21 randomized clinical trials. *J Pain Symptom Manage* 2001;21:511–526.
37. Ekrol I, Duckworth AD, Ralston SH, et al. The influence of vitamin C on the outcome of distal radial fractures: a double-blind, randomized controlled trial. *J Bone Joint Surg Am* 2014;96:1451–1459.
38. Karu T. Primary and secondary mechanisms of action of visible to near-IR radiation on cells. *J Photochem Photobiol* 1999;49:1–17.
39. Stochel G, Stasicka Z, Brindell M, Macyk W, Szacilowski K. *Bioinorganic Photo-Chemistry*. Chichester: John Wiley & Sons, 2009; p. 298.
40. Kertesz I, Fenyö M, Mester E, Bathory G. Hypothetical physical model for laser biostimulation. *Optics Laser Technol* 1982;14:31–32.
41. Friedmann H, Lubart R. Nonlinear photobiostimulation: the mechanism of visible and infrared laser-induced stimulation and reduction of neural excitability and growth. *Laser Ther* 1993;5:39–41.
42. Lubart R, Slnyakov M, Friedman H, et al. Photobiostimulation by visible light: involvement of hydrogen peroxide. *Photo-chem Photobiol* 1999;6:169–174.
43. Lubart R, Friedmann H, Lavie R. Photobiostimulation as a function of different wave-lengths. *Laser Ther* 2000;12: 38–41.
44. Liu TCY, Duan R, Yin PJ, Li Y, Li SL. Membrane mechanism of low-intensity laser biostimulation on a cell. Membrane mechanism of low intensity laser biostimulation on a cell. *Proc SPIE* 2000;4224:186–192.
45. Braddom RL. *Physical Medicine and Rehabilitation E-Book*. Philadelphia: Elsevier Health Sciences 2010; p. 1472.
46. Gulyar SA. BIOPTRON-light therapy and resources of its application in surgery. *Photobiol Photomed* 2012;9: 16–30.
47. Iordanou P, Baltopoulos G, Giannakopoulou M, Bellou P, Ktenas E. Effect of polarized light in the healing process of pressure ulcers. *Int J Nurs Pract* 2002;8:49–55.
48. Monstrey S, Hoeksema H, Depuydt K, Van Maele G, Van Landuyt K, Blondeel P. The effect of polarized light on wound healing. *Eur J Plastic Surg* 2002;24:377–382.
49. Bolton P, Dyson M, Young S. The effect of polarized light on the release of growth factors from the U-937 macrophage-like cell line. *Laser Ther* 1992;4:33–37.
50. Raeissadat SA, Rayegani SM, Rezaei S, et al. The effect of polarized polychromatic noncoherent light (BIOPTRON) therapy on patients with carpal tunnel syndrome. *J Lasers Med Sci* 2014;5:39–46.
51. Simunovic Z, Ivankovich AD, Depolo A. Wound healing of animal and human body sport and traffic accident injuries using low-level laser therapy treatment: a randomized clinical study of seventy-four patients with control group. *J Clin Laser Med Surg* 2000;18:67–73.
52. Stasinopoulos D, Papadopoulos C, Lamnisos D, Stasinopoulos I. The use of BIOPTRON light (polarized, polychromatic, non-coherent) therapy for the treatment of acute ankle sprains. *Disabil Rehabil* 2017;39:450–457.
53. Stasinopoulos D, Stasinopoulos I, Johnson MI. Treatment of carpal tunnel syndrome with polarized polychromatic noncoherent light (BIOPTRON light): a preliminary, prospective, open clinical trial. *Photomed Laser Surg* 2005;23: 225–228.
54. Stasinopoulos D. The use of polarized polychromatic noncoherent light as therapy for acute tennis elbow/lateral epicondylalgia: a pilot study. *Photomed Laser Surg* 2005;23:66–69.
55. Gulyar SA, Nikula TD, Kirilenko EE, Kirilenko EK. *Anthology of Light Therapy*. Medical BIOPTRON Technology. Kyiv: Bogomoletz Institute of Physiology at the National Academy of Sciences of Ukraine, Kiev. 2009; pp. 421–429.
56. Wilsey B, Teicheira D, Caneris OA, Fishman SM. A review of sympathetically maintained pain syndromes in the cancer pain population: the spectrum of ambiguous entities of RSD, CRPS, SMP and other pain states related to the sympathetic nervous system. *Pain Pract* 2001;1:307–323.
57. Schlereth T, Drummond PD, Birklein F. Inflammation in CRPS: role of the sympathetic supply. *Auton Neurosci* 2014;182:102–107.
58. Basford J, Sandroni P, Low P, Hines SM, Gehrking JA, Gehrking TL. Effects of linearly polarized 0.6–1.6 μM irradiation on stellate ganglion function in normal subjects and people with complex regional pain (CRPS I). *Lasers Surg Med* 2003;32:417–423.
59. Liao CD, Rau CL, Liou TH, Tsao JY, Lin LF. Effects of linearly polarized near-infrared irradiation near the stellate ganglion region on pain and heart rate variability in patients with neuropathic pain. *Pain Med* 2017;18:488–503.
60. Huang D, Gu Y-H, Liao Q, Yan XB, Zhu SH, Gao CQ. Effects of linear-polarized near-infrared light irradiation on chronic pain. *Sci World J* 2012;2012:1–4.

Address correspondence to:
Claudia Leitner, PhD
Zepter International
BIOPTRON AG
Sihleggstrasse 23
Wollerau CH-8832
Switzerland

E-mail: leitner@bioptron.com

Received: August 8, 2018

Accepted after revision: October 31, 2018

Published online: February 20, 2019.